

PG904:

# MASTERS RESEARCH PROJECT

PROJECT TITLE:

How Fine Needle Aspiration  
Cytology [FNAC] is useful in the  
histological diagnosis of palpable  
thyroid nodules

Name: Bwaabwa Oten

Year : MMED 4

ID Number: 5963731

Program: MMED (Surgery)

Institution: Fiji School of Medicine

Date Submitted: 30/10/2009

## Table of Content

	<u>Page No.</u>
Acknowledgment	2
Executive Summary & Objectives	3
Introduction	4
Materials & Methods	5
Results	6
Discussion	10
Conclusion	12
References	13

## **Acknowledgements**

This study will be dedicated to all the patients that have suffered and died from thyroid cancers and those that have developed complications following thyroid surgery.

I wish to thank the following people who have helped me to successfully complete this research:

- Dr Eka Buadromo, for allowing us to report on the difficulty of FNAC reporting at CWMH
- Dr Jitoko Cama, for his endless support and encouragement throughout this study.
- Staff at medical record and pathology laboratory at CWMH, for collecting and making sure that I will have access to all in-patient folders and pathology record.
- Nola Vanualailai, at the Epidemiology department, FSM, for her tireless effort in the data analysis.
- Wince Pickering, University of the South Pacific for his assistance in the data format and process.

## Executive Summary

This study was conducted to assess whether fine needle aspiration cytology (FNAC) is useful in the histological diagnosis of palpable thyroid nodules at the Colonial War Memorial Hospital, Suva, Fiji. It was a retrospective review of five years and nine months (Jan 2004 to Sept 2009). There were a total of 107 cases with 99 (92.5%) females and 8 (7.5%) males (male : female; 1:12.4). There were 34 (32%) were Indo-Fijians and 73 (68%) Fijians with racial ratio of 1:2. Age of the patient range from 8 to 69 year with a mean of 40.3 and  $\pm$  13.6. Forty two (40%) were benign lesions, including 2 with no malignancy, 57 (53%) malignant and 8 (7.0%) insufficient. From the benign lesions , 20 (47.6%) were diagnosed as colloid goiter, 20 (47.6%) colloid cyst and 2 (4.8%) having no malignancy.

For the malignant lesions, 32 (56%) were follicular neoplasia, 14 (24.5%) follicular lesions, 9 (16%) suspicious for malignancy and 2 (3.5%) positive for malignancy. There were 8 (7.5%) insufficient cases. Correlation with the final histopathology diagnosis revealed that nearly half of all the cases are either benign or malignant, except for positive for malignancy group, in which all (2) turn out to be malignant (50% papillary and 50% anaplastic). The overall sensitivity was found to be 57.6%, specificity as 42.6%, and accuracy as 49.5%, while positive predictive value (PPV) was 57.6% and negative predictive value (NPV) was 42.4%, false positive rate (FPR) of 47.4% and false negative rate (FNR) of 52.4%. I recommend that FNAC should be ceased as a primary investigation procedure for thyroid nodules for exclusion of cancer as it highly inaccurate resulting in a poor patient management with thyroid nodules.

## Objectives

1. Identify the prevalence of thyroid cancer at Colonial War Memorial Hospital (CWMH) from January 2004 to January 2009
2. Determine the sensitivity and specificity of FNAC in the evaluation of thyroid nodules in CWMH.
3. Determine the cost of FNAC biopsy for thyroid nodule for both diagnostic and non-diagnostic FNAC result at CWMH.
4. Determine the demographic data for patient with thyroid nodules and cancer.

## Introduction

Fine Needle Aspiration Biopsy (FNA) of the thyroid nodule has been used for more than 25 years and is an effective tool for assessing palpable thyroid nodules and diseases<sup>1,2</sup>. Numerous studies have shown excellent efficacy and accuracy of the test approaching 95% - 99% in the assessment of a thyroid nodules, with a sensitivity of 90.0% - 98% and specificity of 93.2% - 99.8%<sup>3, 4, 5, 6, 7, 8</sup>. At Colonial War Memorial Hospital (CWMH), the accuracy of the FNAC is unknown due to a lack of such study thus the rationale for undertaking this research which was further supported by the queries raised during multidisciplinary meeting involving surgeons, pathologists and radiologists regarding the inconsistent correlation between cytological and histological diagnosis for thyroid nodules at CWMH. One of the reasons for this hesitancy in accepting the procedure is the lack of experienced cytopathologist in interpreting the aspirated material.

Colonial War Memorial Hospital, is the largest national referral center in Fiji, catering for 35-45% of the urban population of 424,831<sup>9</sup>.

Thyroid cancer, accounts for 3.43% of the total mortality from all cancers in Fiji in 2008. It affects females sixteen times more common than males with a racial ratio of fifteen to one (15:1), Fijian to Indian<sup>10</sup>.

## Materials and Methods

Cases were retrieved by a combination of computerized and manual retrospective search of all thyroidectomies done between January 2004 and September 2009, at the Colonial War Memorial Hospital, Suva, Fiji. Only cases between 5 to 70 years of age which have available cytological diagnosis prior surgical resection were included in the study. The exclusion criteria includes; cases without cytological, histological diagnosis, missing case note, hospital number or coding, cases from outside CWMH, those with secondary metastatic thyroid tumor and those with a history of neck radiation.

Numerical coding based on the hospital, cytological and histological numbering was used to assign cases and matched the diagnosis for each cases for confidentiality purposes. The cases were retrieved from the operating theater record and the Patis system (patient recording software programme used at CWMH), and the pathology record. Case note from the Medical registry were referred to for confirmation of cases which had error in coding, numbering, operation details and diagnosis.

The technique of aspiration and preparation of smears and staining is similar to previously describe methods<sup>11, 12</sup>. Aspiration is done in the clinic, using a 21G or 23G needle on a 5 – 10 mls syringe without anaesthesia. Multiple passes were made and immediately smeared and fixed on 2 slides. One slide fixed with 2.5% Carbowax in ethanol, air dried and stained with papanicolaou stain. The other is air-dried and then stained with Giemsa stain and then assessed microscopically by the cytopathologist and finally confirmed by the only local pathologist with more than 7 years of experience.

The cytological diagnosis was classified into 6 categories based on our pathologist classification into; insufficient, follicular lesion, follicular neoplasia, suspicious for malignancy and positive for malignancy. This was further divided into Benign, Malignant and insufficient. Benign lesions include colloid cyst, goiter and no malignancy. Malignant lesions include follicular lesion, follicular neoplasia, suspicious for malignancy and positive for malignancy.

Written consent for the study and data collection was obtained from the Head of Surgery and Pathology (CWMH), and approved by the FSMed Ethics Committee.

Statistical analysis was done using Window Excel (Window 2003) and SPSS for Window (Version 14.0; SPSS Inc.,Chicago, Illinois, USA).

## Results

In total, there were 149 thyroidectomies done between January 2004 and September 2009, at the surgical department, CWMH, with ninety (92.5%) females and eight (7.5%) males (male : female; 1:12.4). The median age is 37 (mean  $\pm$  standard deviation, 40.3  $\pm$  13.6). There were thirty four (32%) Indo-Fijians and seventy three (68%) Fijians (Table 1 and figure 1). Forty two (28.2%) cases were excluded with 31 (74%) having no available cytological diagnosis, 9 (21%) without histological diagnosis and 2 (5%) having other diagnosis resulting in a total of 107 (72%) cases available for analysis, with 99 (92.5%) females and 8 (7.5%) males (Table 2 and figure 2).

Table 1.

Ethnicity distribution		
Race	Number	Percentage (%)
Indofijian	34	31.8
Fijian	73	68.2
<b>Total</b>	<b>107</b>	<b>100</b>

Figure 1.

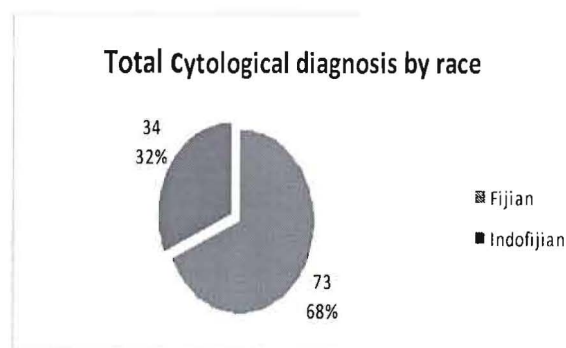
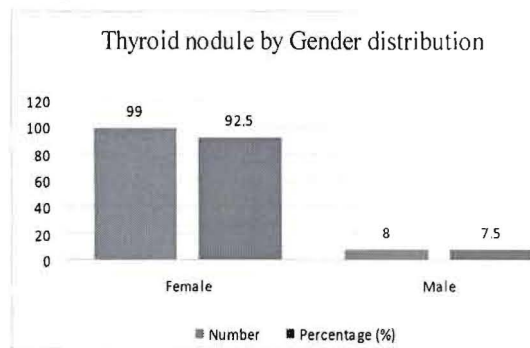


Table 2.

Gender distribution		
Sex	Number	Percentage (%)
Female	99	92.5
Male	8	7.5
<b>Total</b>	<b>107</b>	<b>100</b>

Figure 2.



The age distribution of thyroid cytological diagnosis is shown in figure 3. There were 4 (3.7%) cases less than 20 years of age, 58 (54.2%) between 21 and 40 years, 35 (32.7%) between 41 and 60 years and 10 (9.3%) above 60 years of age. The cytological diagnosis for each age group is summarized in table 3.

Figure 3.

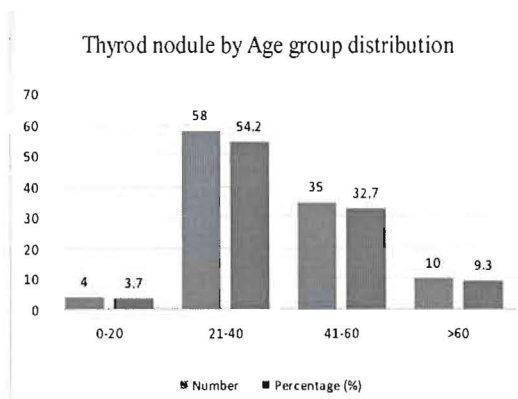


Table 3.

		Differential cytological diagnosis by age group									
Age group	Count	CC	CG	FN	FL	Insufficient	MCA	No Malignancy	PCA	Suspicious	To
0-20	No.	0	1	2	0	0	0	0	0	1	
	(%)	0	0.9	1.9	0	0	0	0	0	0.9	3
21-40	No.	12	13	18	6	4	0	1	1	3	
	(%)	11	12.1	16.8	6	3.7	0	0.9	0.9	2.8	54
41-60	No.	6	5	10	6	2	1	1	0	4	
	(%)	5.6	4.7	9.3	6	1.9	0.9	0.9	0	3.7	32
>60	No.	2	1	2	2	2	0	0	0	1	
	(%)	1.9	0.9	1.9	2	1.9	0	0	0	0.9	9
Total	No.	20	20	32	14	8	1	2	1	9	1
	(%)	19	18.7	29.9	13	7.5	0.9	1.9	0.9	8.4	1

CC indicate Colloid cyst, CG: Colloid goiter; FN: Follicular neoplasia; FL: Follicular lesion; MCA: Medullary carcinoma; PCA: Papillary Carcinoma; No.: Number

For cytological diagnosis, there were forty two (40%) benign lesions, including 2 with no malignancy, 57 (53%) malignant and 8 (7.0%) insufficient (figure 4). From a total of 42 benign diagnosis, 20 (47.6%) were diagnosed as colloid goiter, 20 (47.6%) colloid cyst and 2 (4.8%) having no malignancy. For the malignant group, the majority of the cases were follicular neoplasia accounting for thirty two (56%), 14 (24.5%) were follicular lesions, 9 (16%) suspicious for malignancy and 2 (3.5%) positive for malignancy. There were 8 (7.5%) insufficient cases (Figure 5).

Figure 4.

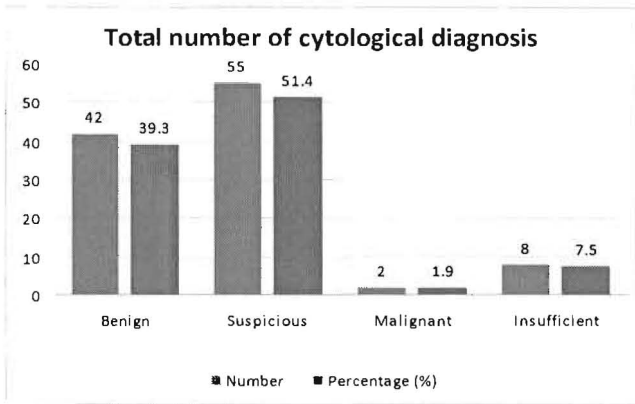
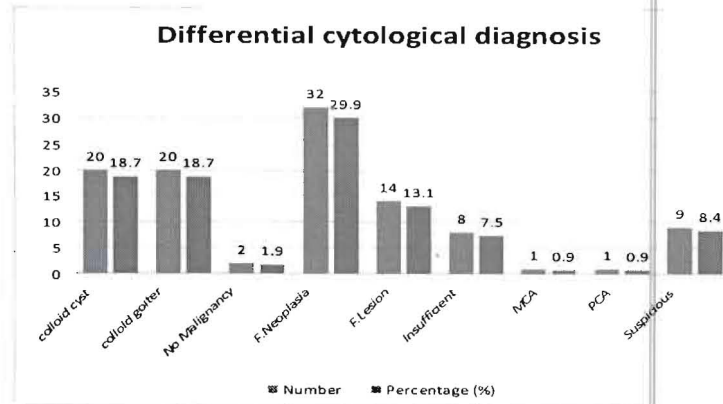


Figure 5.



In the histological diagnosis, 63 (59%) were classified as benign, 42 (39%) malignant, and 2 (2%) others; parathyroid carcinoma (Fijian race). These two cases were included in the analysis as it involved thyroid resection prior establishing the final histopathological diagnosis. Fijians, account for 73 (68%) of the cases and Indo-Fijian constitute the remaining 34 (32%). The majority of the cases were Fijians with 37 (35%) classified as benign, 34 (32%) malignant and 2 (2.0%) others. In the Indo-Fijian group, twenty six (24%) were benign and 8 (7.0%) malignant (fig 6.).

The histological age group distribution showed a similar pattern as the cytological diagnostic distribution with the majority of the cases stretched in the middle age group. There were four (4%) between 0 and 20 years with 2 (50%) benign and 2 (50%) malignant histological diagnosis. In the 21-40 years age group, there were 58 (54%) cases with 32 (55%) benign, 24 (41%) malignant and 2 (3%) others. Thirty five (33%) were in the 41 – 60 years age group with 25 (71%) benign and 10 (29%) malignant. In the above 60 years age group there were 9 (10%) cases with 4 (40%) benign and 6 (60%) malignant (fig. 7)

Figure 6.

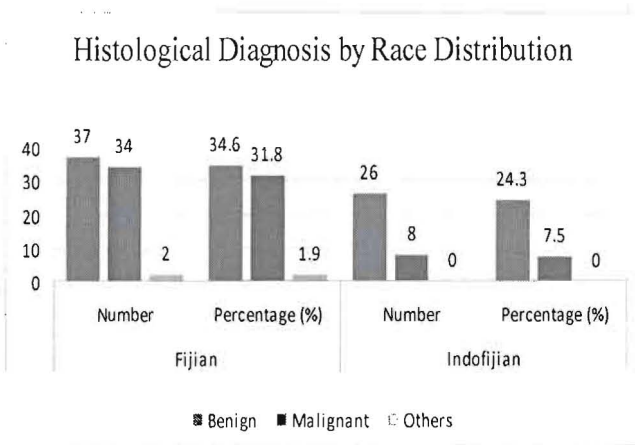


Figure 7.

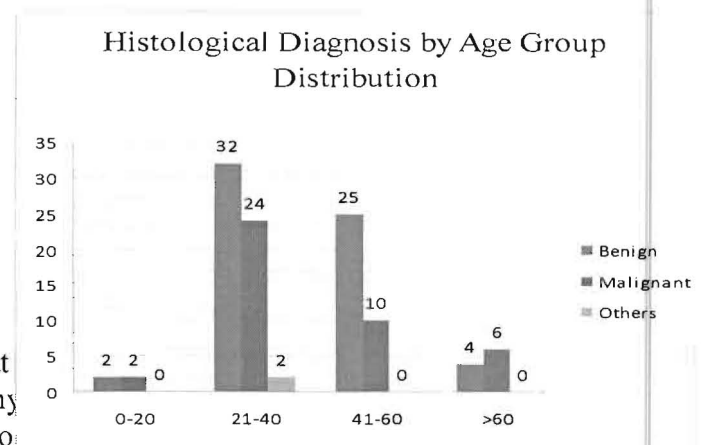




Figure 8.

Thyroidectomy site frequency distribution

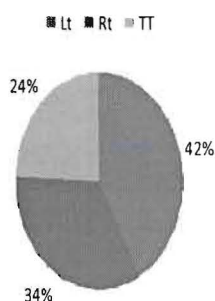


Figure 9.

Histological diagnosis by thyroidectomy Site

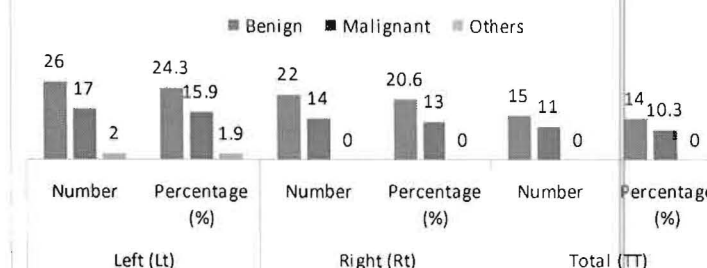


Table 4.

Cytologic - histologic Correlation										
Cytologic diagnosis	No. of patients (%)	Histologic diagnosis: No. of patients (%)								
		CG	CC	MCA	Thyroiditis	FA	HA	FC	PCA	Anaplastic
Insufficient	8 (7.5)	4 (50)	0	0	0	1 (12.5)	0	0	2 (25)	1 (12.5)
Benign	42 (39.2)	18 (43)	1 (2.4)	1 (2.4)	1 (2.4)	4 (9.6)	0	1 (2.4)	16 (38)	0
FL	14 (13)	7 (50)	0	0	0	2 (14.3)	0	2 (14.3)	3 (21.4)	0
FN	32 (30)	13 (41)	0	3 (9)	3 (9)	6 (19)	0	1 (3)	6 (19)	0
Suspicious for malignancy	9 (8.4)	3 (33)	0	1 (11)	1 (11)	0	0	0	3 (33)	1
Positive for malignancy	2 (1.9)	0	0	0	0	0	0	0	1 (50)	1 (50)

CC indicate Colloid cyst, CG: Colloid goiter; FN: Follicular neoplasia; FL: Follicular lesion; MCA: Medullary carcinoma; PCA: Papillary Carcinoma; No.: Number.

A Chi-square (fig 10), was used to calculate the statistical accuracy of the FNAC biopsy. There were 99 cases included with 8 (insufficient cases) excluded. The overall sensitivity was found to be 57.6%, specificity as 42.6%, and accuracy as 49.5%, while positive predictive value (PPV) was 57.6% and negative predictive value (NPV) was 42.4%, false positive rate (FPR) of 47.4% and false negative rate (FNR) of 52.4%.

Figure 10.

Cytopathology result	Histopathology result		Total
	Non-neoplastic	Neoplastic	
Neoplastic	27	30	56
Non-neoplastic	20	22	43
Total	47	52	99

*Sensitivity = 57.7%; Specificity = 42.6%; Accuracy = 49.5%; Positive predictive value = 57.6% and Negative predictive value = 42.4%; False positive rate = 47.4% and False negative rate = 52.4%*

## Discussion

In this study the age of the patient ranges from 8 to 69 years with a mean age of 40.3±13.6. The majority of our cases were aged between 21-40 years i.e 58 (44.2%) cases. There were 4 (3.7%) cases less than 20 years of age, 58 (54.2%) between 21 and 40 years, 35 (32.7%) between 41 and 60 years and 10 (9.3%) above 60 years of age. The cases were much older than a study in Pakistan with a mean age of 35.37 +/- 12.17.<sup>13</sup>

In this study the male to female ratio is 1:12.4, which is 2 time higher than other studies in Pakistan.<sup>13, 14</sup> In my study out of 107 cases, 90 (92.5%) were females and 8 (7.5%) males.

Out of 107 cases, there were 73 (68%) Fijians and 34 (32%) Indo-Fijians, with a ratio of 1:2 (Indo-Fijian to Fijian). The reason for this higher ration for Fijians is their relative higher population number than Indo-Fijians.<sup>9</sup>

In this study, 14 (24.5%) cases were not clearly committed and labeled follicular lesion, on cytologic diagnosis. This group is the main pitfall in FNAC diagnosis for thyroid nodule that is still a prevailing problem in FNAC diagnosis.<sup>13</sup> This could be attributed to avoidance of over commitment to cytology diagnosis which is a major problem in this study.

On comparing the cytologic and histology diagnosis (Table 4), the insufficient group showed that 4 (50%) were benign of which 50% were actual colloid goiter, and 4 (50 %) malignant in which 25% were papillary carcinoma. For the benign group, 20 (48%) were benign in which 43% were colloid goiter and 22 (52%) malignant in which 38% were papillary carcinoma. For follicular lesion, 7 (50%) were benign with 50% being colloid goiter and 7 (50 %) malignant in which 21% were papillary carcinoma. For follicular neoplasia 16 (50%) were benign in which 50% were colloid goiter and 16 (50%) malignant, in which 19% were follicular adenoma and 19% papillary carcinoma. In the suspicious for malignancy group, 4 (44%) were benign for which 33% were colloid goiter and 5 (56%) malignant in which 33% cases were papillary carcinoma. For the positive for malignancy group, 2 (100 %) turn out to be malignant (50% papillary and 50% anaplastic).

My result showed that nearly half of all the cytological diagnosis turned out to be either malignant or benign on histopathology with the exception of Positive for malignancy group which have 100% accuracy in diagnosing thyroid malignancy. However a relatively small number of only 2 (1.9%) is not statistically convincing.

In this study the overall sensitivity was found to be 57.6%, specificity as 42.6%, and accuracy as 49.5%, while positive predictive value (PPV) was 57.6% and negative predictive value (NPV) was 42.4%, false positive rate (FPR) of 47.4% and false negative rate (FNR) of 52.4%.

Comparing my finding with other studies, Bukhari et al, in a cross sectional study of 65 thyroid samples has a sensitivity of 85%, specificity of 80.5%, while PPV was 93% and NPV of was 79.5%<sup>13</sup>. This was similar to Raj et al in a cross sectional study involving 225 patients with a sensitivity of 81% and a specificity of 62%<sup>16</sup> in diagnosing thyroid malignancy. In another study the sensitivity was 86.1% and specificity was 59.7%<sup>17</sup>. The accuracy ranged between 70-97 %<sup>13, 15</sup>. These higher FNAC sensitivity, specificity and accuracy values could be attributed to the experience of the person doing the biopsy and the cytopathologist interpreting it<sup>18</sup>, which is a major drawback at CWMH.

The false negative rate (FNR) is defined as the percentage of patient with benign cytology in whom malignant lesions are later confirmed on thyroidectomy.

The Papanicolaou society of cytopathology has published a guideline for the examination of thyroid nodule<sup>19</sup>. These guideline suggested a false negative (FNR) and false positive rate (FPR) of < 2% and 3% respectively should be achieved.

Some authors<sup>6,15,20</sup> reported FNR ranging from 1.5% to 11.5%. Ashcraft and van Herle noted that FNR results varied in reported series from 2% to 50% and that among 1330 patients, all of whom had a histologic examination, the FNR was 1.7%<sup>21</sup>. Campbell and Pillsbury<sup>22</sup> analyzed combined data from 912 patients with benign cytologic results who had a histologic examination and found a FNR between 0.5% and 11.5%, with a pooled rate of 2.4%. In my study, 22 cases were classified FNR which translated to 52.4%. These cases were however confirmed histologically as papillary carcinoma in 16 cases, follicular carcinoma in 1 case, follicular adenoma in 4 cases and 1 medullary carcinoma. My value is high, and was due to improper sampling, experience with the procedure and with cytologic interpretation by our cytopathologist.

The false positive rate (FPR) indicates that a patient with malignant FNAC result was found on histological examination to have benign lesion. Caruso and Mezzaferrri<sup>15</sup> reported less than 6% FPR while Campbell and Pillsbury<sup>22</sup> reported 1.2%. In my study there were 27 cases as malignant but turnout to be colloid goiter in 23 and thyroiditis in 4. The FPR is 47.4% which is high and non comparable to others studies<sup>15,20,22</sup> that ranges from 0-8%.

The prevalence of thyroid carcinoma in the urban part of Viti Levu, Fiji, in which CWMH cater for 40% it population is 0.10%.

In this study overall accuracy for cytological diagnosis was 49.5%, which relatively low and does not agrees with other studies<sup>15,20</sup>. However, the interpretation error from this study can be reduced if aspirate were obtained from different portions of the nodules in multinodular or large thyroid goiter, an expert cytopathologists to review and interpret the slides, and the use of Ultrasound- guided FNA procedure.

## **Conclusion**

In conclusion I recommend that FNAC should be ceased as a primary investigation procedure for thyroid nodules for exclusion of cancer as it highly inaccurate resulting in poor patient management with thyroid nodules and expensive.

## References

1. Miller JM, Humburger JI, Kini S. **Diagnosis of thyroid nodules: Use of fine needle aspiration and needle biopsy.** *JAMA* 1979; 241:481-484
2. Lowhagen T, Willems JS, Lundell G, Sundblad R, Granberg PO. **Aspiration biopsy cytology in diagnosis of thyroid cancer.** *World J Surg* 1981;5:61-73
3. M. Regina Castro, MD and Hossein Gharib, MD, FACP, FACE. **Thyroid fine -needle aspiration biopsy : Progress, Practice and Pitfalls.** *Endocr Pract.* 2003;9:128-136
4. Gharib H. **Fine-needle aspiration biopsy of thyroid nodules: advantages, limitations, and effect.** *Mayo Clin Proc.* 1994 Jan;69(1):44-9.
5. Arda IS, Yildirim S, Demirhan B, Firat S. **Fine needle aspiration biopsy of thyroid nodules.** *Arch Dis Child.* 2001 Oct;85(4):313-7.
6. Gharib H, Goellner JR. **Fine-needle aspiration biopsy of the thyroid: an appraisal.** *Ann Intern Med.* 1993 Feb 15;118(4):282-9.
7. Lopez LH, Canto JA, Herrera MF, Gamboa-Dominguez A, Rivera R, Gonzalez O, Perez-Enriquez B, Angeles-Angeles A, Letayf V, Rull JA. **Efficacy of fine-needle aspiration biopsy of thyroid nodules: experience of a Mexican institution.** *World J Surg.* 1997 May;21(4):408-11.
8. Zagorianakou P, Malamou-Mitsi V, Zagorianakou N, Stefanou D, Tsatsoulis A, Agnantis NJ. **The role of fine-needle aspiration biopsy in the management of patients with thyroid nodules.** *In Vivo.* 2005 May-Jun;19(3):605-9.
9. F:\research - thyroid\Fiji Islands Bureau of Statistics - Official Statistics for Fiji.mht.
10. Fiji Ministry of Health 2008 Mortality Report
11. Ramzy, I. **Clinical Cytopathology and aspiration biopsy. Fundamental Principles and Practice.** 2nd Ed. U.S.A. McGraw-Hill, 2001;353-355
12. Koss, L.G and Melamed, M.R. **Koss' diagnostic cytology and histopathology bases, Vol 1.(5th Ed).** Philadelphia. JB Lipincott, 2006;1064-1067

13. Mulazim Hussain Burhari, Shahida Niazi, Ghazala Hanif, Shahzad Shafqat Qureshi, Mohammad Munir, Mumtaz Hasan, Samina Naeem. **An updated audit of fine needle aspiration cytology procedure of solidary thyroid nodule.** *Diagnostic Cytopathology.* 2008;**36(2)**:104-112.
14. Hussain N, Anwar M, Nadia N, Zulfiqar A. **Pattern of surgically treated thyroid diasese in Karachi.** *Biomedica* 2005;21:18-20.
15. Caruso D, Mazzaferri EL. **Fine needle aspiration biopsy in the management of thyroid nodules.** *Endocrinologist* 1991;**1**:194-202.
16. M.D.Raj, S.Grodski, M. Yeung and J. Serpell. **Diagnostic lobectomy is not routinely required to diagnose thyroid cancer in nodules greater than or equal to 4 cm in size?.** *ANZ Journal of Surgery.* 2009;79 (1): 18-19
17. Chao TC, Lin JD, Chao HH, Hsueh C, Chen MF. **Surgical treatment of solidary thyroid nodules via fine-needle aspiration biopsy and frozen-section analysis.** *Ann Surg Onco.* 2007;14:712-718.
18. Silverman JF, West RE, Larkin EW, Park HM, Finley JL, Swanson MS et al. **The role of FNAC in the rapid diagnosis and management of thyroid neoplasm.** *Cancer.* 1986; **57**: 1164-1170.
19. Giuffrida D, Gharib H. **Controversies in the management of cold, hot, and occult thyroid nodules.** *Am J Med.* 1995; 99:642-650.
20. Suen KC, Abdul-Karim FW, Kaninsky DB, Layfield LJ, Miller TR, Spires SE et al. **Guidelines of the Papanicolou Society of Cytopathology for the examination of Fine-needle aspiration specimens from thyroid nodules.** *Mod Pathol.* 1996; 9:710-715.
21. Ashcraft MW, Van Herle AJ. **Management of thyroid nodules II: scanning techniques, thyroid suppressive therapy and fine needle aspiration.** *Head Neck Surg.* 1981; 3:297-322.

22. Campbell JP and Pillsbury HC 3d. **Management of the thyroid nodule.** *Head Neck.* 1989; 11:414-25.